

# CHEST<sup>®</sup>

Official publication of the American College of Chest Physicians



## Cardiovascular Effects of Hydrogen Peroxide: Current Status

Harold C. Urschel, Jr.

*Dis Chest* 1967;51:180-192  
DOI 10.1378/chest.51.2.180

The online version of this article, along with updated information and services can be found online on the World Wide Web at:

<http://chestjournal.chestpubs.org/content/51/2/180>

CHEST is the official journal of the American College of Chest Physicians. It has been published monthly since 1935. Copyright 1967 by the American College of Chest Physicians, 3300 Dundee Road, Northbrook, IL 60062. All rights reserved. No part of this article or PDF may be reproduced or distributed without the prior written permission of the copyright holder.  
(<http://chestjournal.chestpubs.org/site/misc/reprints.xhtml>) ISSN:0096-0217

A M E R I C A N C O L L E G E O F



P H Y S I C I A N S<sup>®</sup>

## Cardiovascular Effects of Hydrogen Peroxide: Current Status

HAROLD C. URSCHEL, JR., M.D., F.C.C.P.\*

Dallas, Texas

**I**N AN ATTEMPT TO FIND A BETTER METHOD for oxygenating tissues which would compare with hyperbaric oxygenation, an intravascular technique of administering oxygen in a regional or systemic system,<sup>1-3</sup> employing dilute solutions of hydrogen peroxide ( $H_2O_2$ ) has been evaluated. Hydrogen peroxide is rapidly degraded to oxygen and water by catalase and peroxidases, enzyme systems present in excess quantities in the blood. Following  $H_2O_2$  decomposition in biologic fluids, it was noted that more oxygen was being recovered from such fluids than one would expect from 100 per cent saturation with oxygen at 1 atm. Experiments revealed this to be a simple supersaturation of a liquid with a gas.<sup>4</sup> Hydrogen peroxide releases dissolved oxygen equivalent to that found in solutions under oxygen at 3-8 atmosphere pressure.  $H_2O_2$  administration does not require lung transport. It can be given continuously over long periods of time, it can be administered by a single physician without expensive equipment and large teams, and it avoids compression-decompression hazards, as well as central nervous system and pulmonary toxicity. Hydrogen peroxide has been demonstrated to be an adjunctive source of oxygen for the anoxic or ischemic heart and can improve resuscitation in refractile arrhythmias or cardiac arrest.<sup>1,5,6</sup> Intra-arterial infusion of  $H_2O_2$  has been noted to reverse the atherosclerotic process,<sup>7,8</sup> potentiate the effect of irradiation on malignant tumors,<sup>9,10</sup> increase the localization of radioactive isotopes in malignant tumors,<sup>11,12</sup>

protect against *Clostridium welchii* infections,<sup>13</sup> promote wound healing<sup>14</sup> and serve as an excellent source of regional oxygenation without significant systemic toxicity.

### CARDIAC EFFECTS OF HYDROGEN PEROXIDE

#### *Direct Tissue pO<sub>2</sub> Measurements (Myocardium)*

Direct  $pO_2$  measurements taken in rabbit myocardium during (1) the intra-arterial infusion of dilute  $H_2O_2$  into the coronary arteries, and (2) the direct application of dilute  $H_2O_2$  to the epicardium demonstrate the relative increase in myocardial  $pO_2$  during the intra-arterial infusion of  $H_2O_2$  to the coronary arteries (Fig. 1) and by the direct diffusion (Fig. 2) respectively.<sup>1</sup>

#### *Oxygenation of the Ischemic or Anoxic Myocardium of Small Animals: Tracheal Occlusion*

The myocardium of rabbits was rendered anoxic by tracheal cross-clamp.<sup>1</sup> These animals were divided into three groups of ten animals each: in Group 1,  $H_2O_2$  was infused into the coronary arteries; in Group 2, it was perfused intrapericardially; in Group 3 (controls), the carrier solutions were administered by each of the two routes, but without  $H_2O_2$ . In Groups 1 and 2, animals treated with 0.12-0.72 per cent  $H_2O_2$ , the arterial blood pressure fell to 0 between 12-15 minutes in contrast to six minutes for the controls, and the arterial pH fell to 7.0 from 10 to 15 minutes in Groups 1 and 2 in contrast to six minutes for Group 3. Cardiac activity in Groups 1 and 2 remained relatively normal and neither nodal rhythm nor cardiac arrest occurred within 120 minutes of observation in contrast to Group 3 where arrhyth-

\*Director, Cardio-pulmonary Section, Sammons Research Laboratory, Baylor University Medical Center; Assistant Clinical Professor of Thoracic Surgery, University of Texas Southwestern Medical School.

mias and nodal rhythm appeared in an average of five minutes and cardiac arrest from 10-16 minutes in all animals. All animals in Group 3 developed cardiac arrest, and, following failure of standard resuscitative methods, most could be revived by adding  $H_2O_2$  to the heart by whichever route of administration of carrier solution was being employed.

#### Coronary Artery Ligation

In another group of rabbits, the myocardium was rendered anoxic and ischemic by ligation of coronary artery branches singly or in combination.<sup>1</sup> Because of the nature of rabbit myocardium, it was impossible in 20 animals to produce a standard ischemic lesion which was reproducible from animal to animal with regard to ECG or blood pressure changes. This made it necessary to evaluate the reversal of ischemic myocardial changes by regional ap-

plications of  $H_2O_2$  within a given animal rather than by comparison of the effect on a standard lesion in a large number of animals. Following ligation of a variety of coronary arteries including the circumflex, the anterior descending, and the right coronary (or a combination of these), dilute  $H_2O_2$  (range 0.06-0.72 per cent) was infused antegrade into the coronary arteries by a slow drip or perfused inside the pericardium at the time of ligation. Specific ECG abnormalities associated with myocardial ischemia, such as ST segment elevation, elevation or depression of the T wave, nodal block, and ventricular tachycardia or fibrillation, could be readily and often repeatedly reversed in the animals by application of the  $H_2O_2$ . A blood pressure drop associated with cardiac arrhythmias could also be reversed, but less consistently (Fig. 3-4).

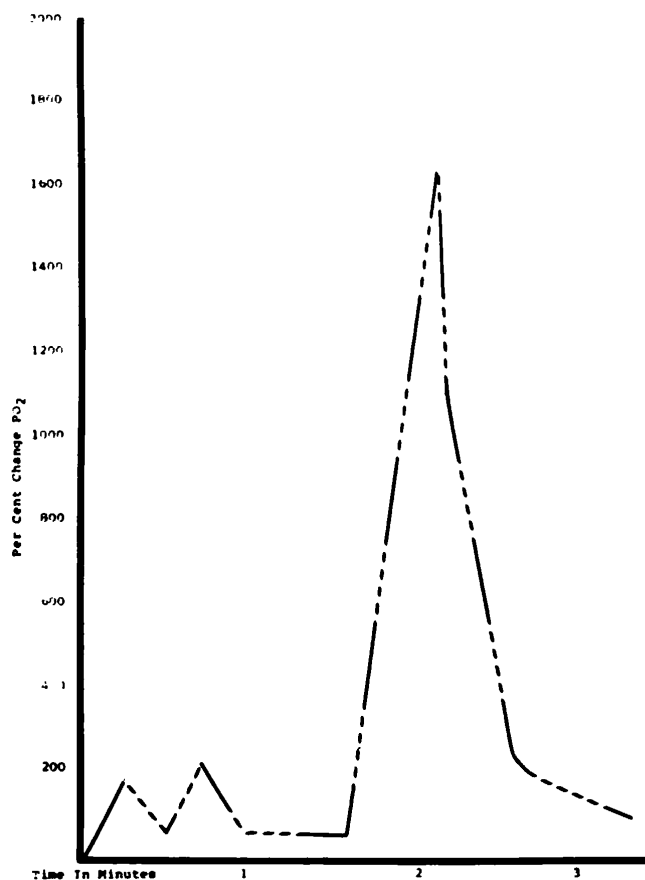


FIGURE 1: Changes in myocardial oxygen tension following coronary artery infusion of 0.36 per cent hydrogen peroxide.

### *Myocardial Protection during Ischemia in Large Animals*

To evaluate the effect of  $H_2O_2$  in protecting a thicker ischemic myocardium, where diffusion is a more important factor, pigs weighing 40-80 kg underwent ligation of the right coronary artery and 50 per cent of the anterior descending vessel. Two groups of ten pigs each were studied: Group 1 to evaluate the effect of intrapericardial  $H_2O_2$  perfusion during coronary artery ligation, and Group 2 to serve as controls.<sup>14</sup>

In Group 1, two plastic No. 190 polyethylene catheters were sutured into the pericardium—one for inflow and the other for outflow. The epicardium was perfused with a Harvard constant-infusion pump, and a steady flow of Hank's solution with 0.06 per cent  $H_2O_2$  at 37° was constantly infused into the pericardium at the rate of approximately 400 ml/hour. In the ten

control animals, the same experiment was conducted with carrier solution alone without  $H_2O_2$ .

In group 2, ventricular fibrillation occurred between two and 32 minutes in all but one animal (average time 12 min). (Table 1). Resuscitation by cardiac massage and defibrillation was successful in seven animals, but failed in two. After return of regular sinus rhythm, mean blood pressure remained less than the original control value of 100 mm Hg in all but three animals, the average being 30-70 mm Hg mean arterial blood pressure. These animals developed ventricular fibrillation several times and could be resuscitated, but they never maintained normal arterial blood pressure. Survival time ranged from two minutes to two hours, the average being 20 minutes. Myocardial tissue  $pO_2$  values were much lower than original control values in all cases. Necropsy examina-

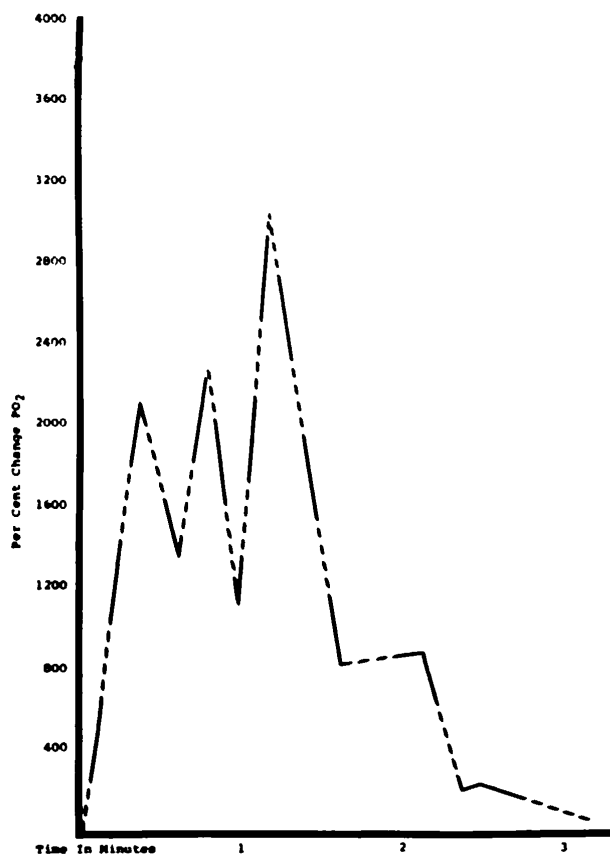


FIGURE 2: Changes in the myocardial tissue oxygen tension following the direct epicardial application of 0.36 per cent hydrogen peroxide.

tion of all pigs revealed a large area of gross infarction over the lower right and left ventricles, with distal infarction in the septum.

In the Group 1 animals treated with 0.06 per cent  $H_2O_2$  in Hank's solution, five animals never developed ventricular fibrillation; in the other five, onset occurred between five and 30 minutes (average time 20 min). Resuscitation by cardiac massage and electrical defibrillation was successful in all cases. Nine animals survived three hours and were sacrificed. One expired at two hours (Table 2). All maintained normal blood pressure (mean value 100 mm Hg) and normal to slightly elevated tissue  $pO_2$  in comparison to the control preligation values. The infarcted area was in a similar location to that of control animals, but it was much less extensive and limited

primarily to the subendocardial area and the distal septum.

In all control animals, after a terminal episode when no blood pressure or cardiac activity was obtainable by standard resuscitative methods, dilute  $H_2O_2$  solutions were added to the myocardium. In four animals, resuscitation was successful despite massive infarctions and systemic acidosis.

Although this method of application is limited by the diffusion of  $H_2O_2$  through the thick myocardium, and although the septum does not appear to be protected by the epicardial application, the improved protection of the treated animals, when compared to controls, appeared significant. No toxicity was demonstrated during therapy.

Employing the same standard coronary artery ligation, other experiments were performed to evaluate coronary artery and right atrial infusion of dilute hydrogen peroxide. These animals received some protection and did better than the control group in which carrier solutions alone were used; however, the duration of protection was much less than those treated by intrapericardial perfusion of  $H_2O_2$ .

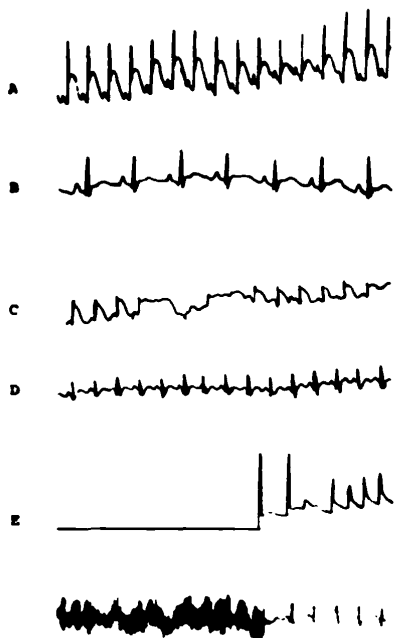


FIGURE 3: Electrocardiographic changes in rabbits with ischemic myocardium during application of dilute hydrogen peroxide. A—5 minutes post-ligation of circumflex. Note elevation of S-T segment; B—2 minutes after infusion of 0.48 per cent hydrogen peroxide in 5 per cent dextrose in water; C—8 minutes post-ligation of proximal and distal descending circumflex branches of L. coronary. Note elevation of S-T segment; D—30 seconds after direct application of 0.24 per cent hydrogen peroxide; E—Note fibrillation; arterial pressure zero to arrow. At this point direct application of 0.24 per cent hydrogen peroxide to myocardium produced resumption of beat and a rise of arterial pressure to 50 mm/Hg.

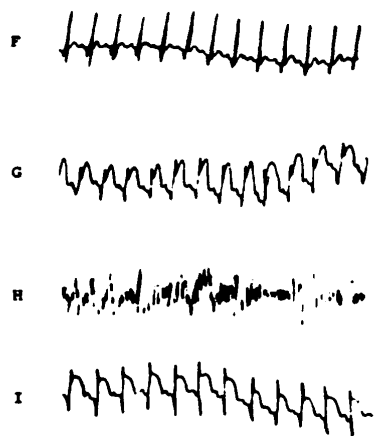


FIGURE 4: Electrocardiographic changes in rabbits with ischemic myocardium during application of dilute hydrogen peroxide. F—Control ECG with the chest open and the animal breathing 100 per cent oxygen. BP 140/110; G—ECG taken 2 minutes after ligation of the distal descending circumflex branch of the left coronary artery. BP 85/70; H—Fibrillation 3.5 minutes after ligation. BP 0; I—ECG 5 minutes after direct application of 0.36 per cent hydrogen peroxide and 20 minutes after the beginning of fibrillation. BP 90/75.

Dimethyl sulfoxide (DMSO) was evaluated as an agent which theoretically might increase diffusion of the  $H_2O_2$  through the thick myocardium and also counteract the vasoconstriction effect of oxygen on the small arterioles. Although the initial results of combining 10 per cent DMSO with .06 per cent  $H_2O_2$  in rabbit hearts undergoing ischemia appeared beneficial.<sup>9</sup> No significant advantage could be observed when employed in larger porcine hearts.<sup>5,15</sup>

#### *Effect of $H_2O_2$ on Totally Ischemic Hearts During Aortic Cross-Clamping*

In an effort to evaluate the effect of  $H_2O_2$  on the totally ischemic heart of large animals with thick ventricles, dogs,\* calves, and goats were placed on cardiopulmonary bypass and the aorta was cross-clamped for one to two hours.<sup>5,6,16</sup> Hydrogen peroxide was applied directly to the epicardium, perfused retrograde through the coronary sinus, infused through the coronary arteries, or instilled intraventricularly (or combinations of these methods were used). Experiments were carried out at normothermia to evaluate the effectiveness of  $H_2O_2$  as the only source of oxygen for the heart. Twen-

\*Since dogs do not have adequate quantities of catalase for  $H_2O_2$  decomposition, this enzyme was added in all canine experiments. This is expensive and involves an additional variable which makes the dog an undesirable experimental animal for  $H_2O_2$  investigation. Rabbits, pigs, goats and humans appear to have adequate amounts of catalase for regional  $H_2O_2$  application.

TABLE 1—EFFECTS OF PERICARDIAL PERFUSION OF  $H_2O_2$  AND CONTROL PIGS AFTER CORONARY ARTERY LIGATION

	Control Carrier Sol. Only)	Treated $H_2O_2$
Incidence of ventricular fibrillation	9/10	5/10
Average onset time of ventricular fib.	12 min.	20 min.
Reversibility of ventricular fib.	7/9	10
Av. no. shocks to reverse ventricular fib.	5	1-2
Normal mean arterial blood pressure	4/10	9/10
Myocardial tissue oxygen tension	Less than control	Normal or greater than control

ty-five control animals (ten dogs, five goats, and ten calves) were studied in similar fashion for comparative analysis. All animals were anesthetized with endotracheal halothane and placed on total cardiopulmonary bypass, and the aortas were cross-clamped 60-120 minutes. The hemiazygos vein was ligated at its entry to the coronary sinus, providing a totally anoxic heart, except for the oxygen supplied by  $H_2O_2$ . The hearts were vented through the left and right ventricular apices for decompression. After removal of the aortic cross-clamp, the coronary arteries were again perfused with blood, and sufficient time was allowed for normal cardiac rhythm to return without artificial resuscitation.  $H_2O_2$  application (0.06-0.24 per cent) began when the aortic cross-clamp was placed.

The hearts of all animals fibrillated within 30 minutes, most fibrillating between five and 15 minutes. None of the control animals could be resuscitated after one hour of aortic cross-clamping, and most could not be resuscitated after 30 minutes. Average time of successful resuscitation in dogs was after 20 minutes of aortic cross-clamping; for calves and goats, it was approximately 40 minutes. In the treated animals, after one hour of aortic cross-clamping, reversal to regular sinus rhythm was fairly consistent with most methods of  $H_2O_2$  application. Beyond this, however, protection was sporadic. Most hearts required direct-current defibrillation and some required calcium and epinephrine injections into the aortic route to reverse ventricular fibrillation to regular sinus rhythm (Table 3). Coronary artery infusion for over 60 minutes was not protective when employed alone, and when combined with

TABLE 2—SURVIVAL OF PIGS TREATED BY PERICARDIAL PERFUSION OF  $H_2O_2$  AFTER CORONARY ARTERY LIGATION

Hrs.	Control	$H_2O_2$
0*	2	0
1	5	0
2	1	1
3	2	9

\*Initial ventricular fibrillation fatal.

epicardial application, the results were no better. Coronary sinus retrograde perfusion alone also failed to protect the heart. Epicardial application and coronary sinus perfusion protected 50 per cent of the animals, some tolerating 100 minutes of aortic cross-clamping. The best protection was achieved with epicardial application, coronary sinus perfusion, and intraventricular instillation of  $H_2O_2$ .

Despite reversion to regular sinus rhythm, most of the animals could not maintain circulation off cardiopulmonary bypass, indicating only partial protection by the  $H_2O_2$  and failure to support the whole heart during this length of ischemia at normothermia. Five calves maintained normal blood pressure when aortic cross-clamping lasted only 60 minutes, and these were long-term survivors of two weeks or more. Two dogs maintained normal blood pressure off cardiopulmonary bypass when aortic cross-clamping lasted less than 45 minutes, a significantly longer time than in control dogs. The long-term survivors showed no evidence of  $H_2O_2$  toxicity.

Myocardial tissue  $pO_2$  levels in the  $H_2O_2$ -treated animals were equal to or greater than control levels during the ischemic phase. In the control groups, these values fell much below the original control values, in some animals reaching zero.

The epicardium appeared white after  $H_2O_2$  oxygenation, but color returned on perfusion of the coronary arteries with blood. The opened hearts of the survivors had normal ventricular and atrial walls with occasional brownish areas in the septum. The hearts with prolonged ischemia, which failed to resume normal rhythm, showed moderate superficial edema, grossly normal atria, and normal ventricular walls two-thirds through their thickness from the epicardial surface. From there to the endocardial surface, the muscle appeared blue and ischemic except in the animals treated by intraventricular instillation of  $H_2O_2$ . In these hearts, the myocardium appeared normal. In the animals not treated by coronary artery or coronary sinus perfusion, the septum appeared bluish-black in areas, suggesting ischemia. The micro-

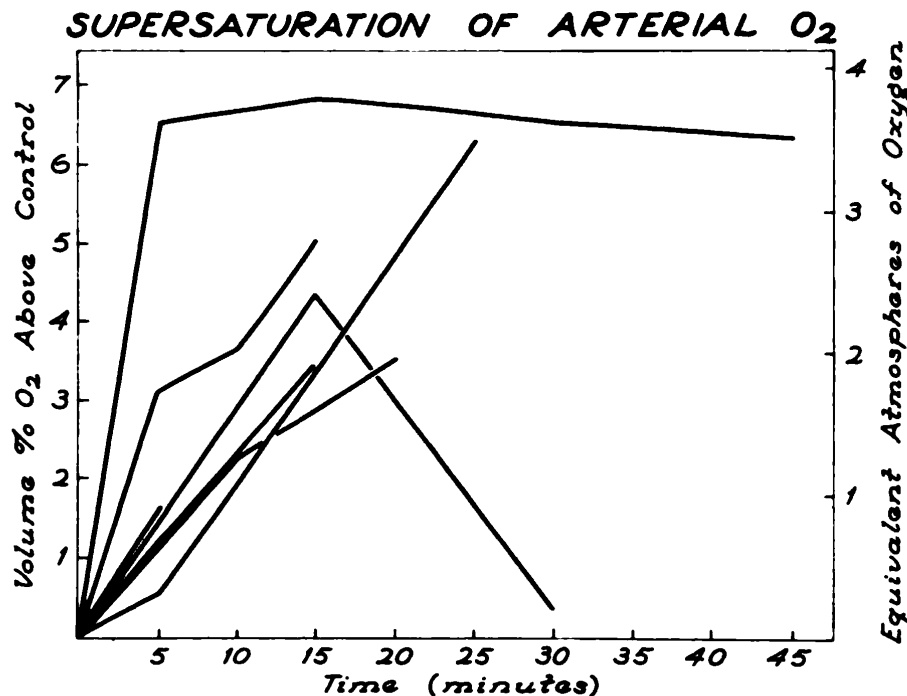


FIGURE 5: The increase in left atrial oxygen content following nebulization of hydrogen peroxide and concentrations from 1 to 6 per cent. Each line represents a different rabbit treated with a different concentration from 1 to 6 per cent.

scopic findings were consistent with the gross pathologic appearance.

Hydrogen peroxide appears to prolong the safe period of myocardial ischemia, but not consistently beyond 60 minutes. Survivors showed no evidence of  $H_2O_2$  toxicity. The diffusion factors in the thick myocardium suggest that epicardial application or coronary artery infusion alone cannot protect the myocardium for long periods of time. Coronary artery infusion alone may carry the hazard of vasospasm despite administration of vasodilator agents such as papaverine. As the myocardium becomes thicker, problems of oxygen diffusion become more difficult. The conduction mechanism is not well protected by epicardial application alone, but  $H_2O_2$  seems to have some value when given intraarterially or retrograde by coronary sinus perfusion. The intraventricular  $H_2O_2$  seems to aid diffusion through the thick-walled myocardium as well as through the septum. The absence of blood flow through the heart to remove any waste products may be a problem in  $H_2O_2$  application. Certainly other factors, such as carbon dioxide transport and acidosis, contribute to prolonged inadequate protection by  $H_2O_2$  alone. This suggests that  $H_2O_2$  may be an important adjunct in the treatment of myocardial ischemia and anoxia, but its application may be limited in total support of the bloodless heart.

#### *Clinical Trial*

Because of the apparent advantages in myocardial support during anoxia,  $H_2O_2$  was used to treat a 60-year-old white female for vascular collapse of unknown etiology, unresponsive to the conventional methods of resuscitation.<sup>8</sup> A cardiac catheter was passed through the right brachial artery to the root of the aorta. ECG and blood pressure were monitored. Within one minute after the infusion of 0.12 per cent  $H_2O_2$ , the ECG reverted from a nodal to a regular sinus rhythm, and the mean arterial pressure increased from 35 to 70 mm Hg within three minutes. Within ten minutes after the infusion was stopped, the ECG again reverted to nodal rhythm and

the blood pressure dropped. This sequence was repeated five times during a 12-hour period, reversal of ECG abnormalities and hypotension being achieved with each infusion of  $H_2O_2$ . The patient eventually expired when  $H_2O_2$  therapy was stopped.

#### ASSISTED SYSTEMIC OXYGENATION WITH HYDROGEN PEROXIDE

Dilute  $H_2O_2$  was administered to rabbits by three different techniques, to supply oxygen systematically: (1) by peritoneal perfusion,<sup>8</sup> (2) by rectal perfusion,<sup>8</sup> and (3) by ventilation with an  $H_2O_2$  aerosol.<sup>17</sup>

#### *Peritoneal Perfusion of Hydrogen Peroxide*

For studies on peritoneal perfusion of  $H_2O_2$ , rabbits were anesthetized with sodium pentobarbital, intubated, and placed on IPPB (intermittent positive pressure breathing) apparatus with 100 per cent oxygen in order to maintain a constant ventilation rate and 100 per cent arterial oxygen saturation. A midline incision was then made to expose the portal vein, and a flanged PE-90 catheter was secured in the vein with a purse-string suture and withdrawn to the flange so as not to obstruct venous flow. A dialysis kit (Baxter K-128) was secured in the peritoneum and the wound closed. The peritoneum was perfused with warm dilute  $H_2O_2$  solutions (0.12-0.48 per cent), and blood samples were collected periodically from the portal vein.

The oxygen content of the portal vein blood during dialysis approximated that in the arterial blood. The carbon dioxide content of the venous blood could be adjusted by varying the pH of the buffer system of the  $H_2O_2$ . In the pilot studies, the carbon dioxide could not be adjusted to a degree necessary for systemic maintenance; however, this may be possible after further investigation.

#### *Rectal Perfusion of Hydrogen Peroxide*

Studies on rectal perfusion of  $H_2O_2$  were conducted in dogs, and, as in the rabbits, a catheter was placed in the portal vein for blood sampling. The large bowel was perfused via the rectum with dilute  $H_2O_2$ , and



blood samples were collected from the portal vein during perfusion. As in peritoneal perfusion, the oxygen content of the portal vein blood approximated that of 100 per cent saturated arterial blood. No attempt has been made to adjust carbon dioxide by this procedure.

#### *Ventilation with an Hydrogen Peroxide Aerosol*

Rabbits anesthetized with sodium pentobarbital were intubated and placed on 100 per cent oxygen on a Bird respirator. The chest was opened between the fourth and fifth intercostal spaces, the pericardium slit, and a flanged PE-90 catheter secured into the left atrium by a purse-string suture. The chest was closed and the animal allowed to breathe 100 per cent oxygen for 30 minutes before aerosol  $H_2O_2$  was given. Concentrations of  $H_2O_2$  from 1 per cent to 6 per cent in normal saline were nebulized as an aerosol.

After nebulization therapy, the left atrial blood of these animals was found to be "supersaturated" with oxygen containing quantities equivalent to that expected with oxygen administration at 3 atm. When this value was exceeded, small bubbles began to appear in the samples. Figure 5 shows the effects of different  $H_2O_2$  concentrations. An abrupt drop in atrial  $pO_2$  occurred in the animal given  $H_2O_2$  by aerosol, but it was felt that this animal developed bronchospasm. The 1 per cent aerosol, which was least irritating, provided as good arterial oxygen concentration as the higher concentrations.<sup>7</sup>

#### VASCULAR EFFECTS OF HYDROGEN PEROXIDE

##### *Effect of Intra-arterial Hydrogen Peroxide in Arteriosclerosis*

Kann, Mengel, Hochstein and others have shown that the formation of lipid peroxides is one sequela of exposure to oxygen at high pressure. We have noted a consistent reduction in the severity of atherosclerotic disease in the infused area of patients receiving intra-arterial hydrogen peroxide. Pilot experiments have been per-

formed in our laboratory to investigate this observation.<sup>7a</sup>

(1) Gross, histologic and chemical evaluation of aortas taken at post mortem from patients treated for extended periods with intra-arterial hydrogen peroxide.

Several patients who have been infused intra-arterially with hydrogen peroxide as an adjunct to irradiation therapy in the management of their malignant disease have undergone post mortem examination. During the necropsy the catheter was left in place, the aorta was split longitudinally and the tip of the catheter marked. Sections were prepared from the aorta immediately above and below the catheter tip for comparative histologic evaluation by Oil Red O and H and E stains. Weighed sections of the vessel were then prepared for total lipid analysis. The components (cholesterol, cholesterol esters, phospholipids, triglycerides and free fatty acids) were separated by thin-layer chromatography. The material was taken from the thin-layer chromatogram and quantitated by gas chromatography.

In all cases studied to date, the patients received hydrogen peroxide infusion alone as an adjunct to other modes of therapy for a variety of conditions over extended periods of time ranging from 4-16 weeks. During this time, the individuals received daily infusions of 250 ml of hydrogen peroxide in "Ionosol-T" with a peroxide concentration ranging from 0.36 per cent to 0.48 per cent. Upon gross examination, the segment of the aorta being infused was found to be different from the area not being infused. This difference was marked by a decrease in the number and severity of atheromatous plaques and an increase in flexibility and elasticity of the vessel. The thoracic aorta contained numerous atheromatous plaques, some of which are eroding into the lumen. Ordinarily one expects to find an increase in number and severity of the atheromatous lesions from the thoracic to the abdominal aorta. In these patients, where the catheter was in the abdominal aorta below the renal ar-

teries, there was a lack of raised lesions from the point of the catheter to the bifurcation, and the iliacs were relatively free of gross disease except for some intimal and subintimal fibrosis. Histologic evaluation by Oil Red O stained sections showed a decrease in total subintimal lipid deposits. When weighed samples of the vessels were extracted and total lipids determined, it was found that approximately a 50 per cent reduction in total lipids (10-40 per cent decrease in cholesterol and 20-50 per cent decrease in cholesterol esters) had occurred in the area being infused with hydrogen peroxide.

(2) *In vitro* studies of human aortas incubated with dilute hydrogen peroxide in saline or incubated in saline under oxygen at increased pressure.

Aortas were procured at post-mortem from a number of adults who had expired for a variety of reasons, but who had received no hydrogen peroxide during their hospital course. The tissue from several aortas was cut into 5 mm squares, pooled, washed 15 times in cold saline and divided into a number of 15 gm samples. These samples were divided into three parts; one sample was incubated in 100 ml of a 0.36 per cent hydrogen peroxide in saline, the second sample was incubated in 100 ml of saline under oxygen at 2,4 and 6 atmospheres absolute pressure, and the third sample was incubated in 100 ml of saline

in room air normal pressure, the latter serving as a control. After two hours of incubation, the tissue was removed by two filtrations, the lipid extracted from the resulting fluid and analyzed as described earlier.

The relative quantities of lipid in the fluid following incubation of human aortas in 0.36 per cent hydrogen peroxide or in saline under oxygen at 6 atmospheres absolute pressure were significantly higher than the controls. A slightly higher total lipid value was achieved with hydrogen peroxide when compared to oxygen at 6 atmospheres absolute. Only a trace of lipid was detected in samples incubated in saline at normal pressures.

(3) *In vivo* studies of changes in total serum in humans following the intra-arterial infusion of hydrogen peroxide.

Venous blood samples were collected from the cubital vein immediately before and after the infusions of .24-.48 per cent  $H_2O_2$  into the abdominal aorta with a total time lapse between the two samples of 20-30 minutes. Serum lipid determinations were carried out as described earlier. It was noted that the total amount of increase in lipids following the infusion seems to be related to both severity of disease and concentration of hydrogen peroxide infused.

#### *Clinical Trial*

A 59-year-old woman with severe basilar artery insufficiency secondary to inoperable

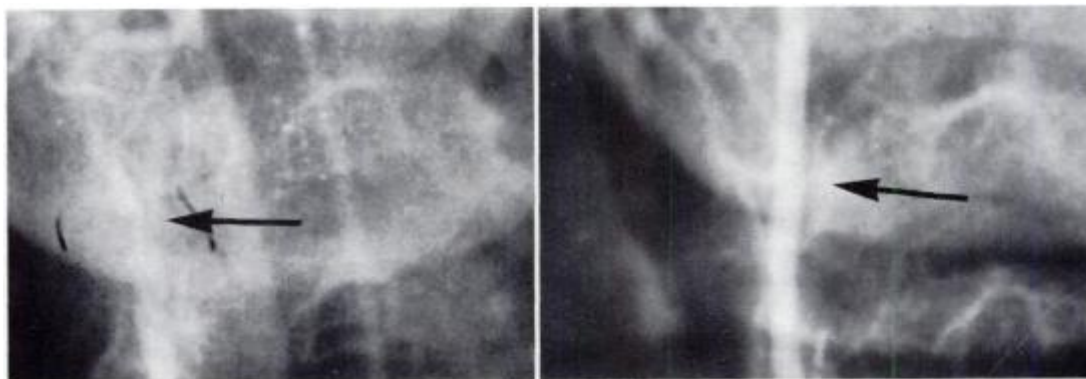


FIGURE 6A

FIGURE 6B

FIGURE 6: Right vertebral arteriogram performed by retrograde innominate artery injection before (A) and after (B) intra-arterial  $H_2O_2$  therapy demonstrates apparent diminution in the arteriosclerotic stenosis of the mid-vertebral artery.

arteriosclerotic stenosis of her mid right vertebral artery, whose symptoms were progressive on heparin therapy, was treated by intra-arterial  $H_2O_2$  in October 1966. Her left vertebral artery was congenitally small and both carotid arteries were patent. An indwelling catheter was placed retrograde into the innominate artery through a branch of the thyrocervical trunk. Over 29 days, she was given 100 treatments, each consisting of .12 per cent  $H_2O_2$  in 5 per cent D and W and 12 mg of tolazoline (Priscoline) at a rate of 18 ml/min.

Her symptoms, which were progressive, appeared to stabilize and possibly improve on early evaluation. The arteriogram following  $H_2O_2$  therapy, in contrast to that obtained before treatment, revealed an apparent decrease in the arteriosclerotic stenosis (Fig. 6a, b) and less delay in the vertebral artery filling time when compared to the carotid artery. A long-term follow-up will be necessary to evaluate the neurologic and arteriographic result.<sup>10</sup>

#### *Potentiation of Effect of Irradiation Therapy on Malignant Tumors by Intra-arterial Hydrogen Peroxide*

One of the basic radiobiologic concepts dealing with the lethality of ionizing radiation is concerned with the oxygen concentration in a tissue at the time of its exposure to radiation. It has been known that the slope of the radiosensitivity curve increases steeply as the oxygen concentration increases above anoxia, and at high oxygen concentration reaches a maximum sensitivity, which is difficult to exceed by increasing the amount of oxygen present. Due to the innate anoxic character of neoplastic tissue and the fact that the greatest increase of radiosensitivity is seen at the lower oxygen levels, the oxygen effect is more pronounced in some tumor tissue than in the corresponding or adjacent normal tissue. Therefore, the radiotherapeutic ratio can be favorably influenced by increasing the oxygen in the region of the tumor. Various groups have used hyperbaric oxygen to achieve this result in the treatment of malignant tumors. Our group

has used intra-arterial hydrogen peroxide in a regional system to achieve the same result.<sup>10,19,21</sup>

A catheter is introduced into the artery supplying the neoplasm under direct surgical exposure and left in place for several weeks. At the present time, the following three areas are used: the external carotid artery is preferably used for treatment of head and neck malignancies, the brachial or femoral arteries for extremity tumor therapy and the abdominal aorta retrograde through the femoral artery for therapy of malignant disease in the abdomen and pelvis. The infusions and standard protracted external irradiation to an expected 100 per cent tolerance dosage is given daily. The irradiation therapy is carried out during the latter portion of the infusion and the infusion is terminated following the radiation.

Care is taken with infusion of solutions of hydrogen peroxide to avoid severe vessel spasm and bubbling. With careful individualization and experience, all significant complications such as infection, clotting, etc., have virtually been eliminated.

From 1961 through 1965, 131 patients with malignancies have been treated using this technique. We have selected patients who in our opinion had less than a 10 per cent chance of surviving three years if the accepted forms of therapy had been employed. Although the number of patients are small and the number of variables great, the 44 per cent three-year survivals in this group of patients with advanced disease appears significant. Specifically, we are encouraged with the results to date in the head and neck series, advanced cervix and ovary, recurrent carcinoma of the colon and carcinoma of the bladder. The results in the carcinoma of the bladder appear specifically significant when considered in the light of our dosage of 4500 rads in four weeks to the entire pelvis.

#### *Preferential Localization of Radio-isotopes in Malignant Tissue by Intra-arterial Hydrogen Peroxide*

It has been observed that when certain

isotopes were given intra-arterially following the intra-arterial infusion of hydrogen peroxide, the isotope localized preferentially in the area of the malignant tumor in the infused field.<sup>11,19,20,22</sup> These studies were extended and conducted in rats, using the Walker 256 carcinosarcoma; in rabbits, using the VX-2 carcinoma; and in humans having a variety of malignancies.

Utilizing HELA cells and KB cells has allowed us to demonstrate selective uptake of radioactive iodinated blood albumin (RISA) under the direct influence of hydrogen peroxide. The process is reversible, such that the application of hydrogen peroxide and its withdrawal prior to the addition of the isotope reveals virtually no uptake of the large molecule isotope. Similar, but as yet incomplete studies using the same modality under hyperbaric conditions of 2 to 6 atmospheres demonstrate the same phenomena, and this also appears to be reversible. The mechanism is unknown as yet, but the selective reaction of normal cells to tumor cells appear to be in a ratio of approximately 1:5. In addition, the effective half-life of the isotope is prolonged because of the considerable increase in time that the isotope remains inside the cell. Autoradiographic studies using the electron microscope at 40,000 x show the distribution to be predominantly at the cell wall, and within the nucleus.

Subsequent studies utilizing VX-2 symmetrical hind leg tumors in rabbits, catheterizing both iliac arteries individually, flushing the left with 7 ml of carrier solution, 10 microcuries of RISA, and following with 3 ml of carrier solution show little or no concentration of RISA at 48, 72, or 96 hours. The right leg was infused in the same manner with the exception of .12 per cent hydrogen peroxide concentration in the carrier solution. In contrast to the control, the right leg showed considerable concentration of the isotope within the tumor at 24, 48, 72, and even 96 hours. Forty animals were tested this way and all demonstrated the same phenomenon.

Retrospective type human scanning studies were then carried out. Seventy-eight scans have been done. The procedure used entailed doing a percutaneous puncture of either the femoral or the carotid artery with a 19-gauge Courmand needle. A catheter is then threaded through the needle until the tip is at the desired level, 200 ml of from .12 per cent to .48 per cent hydrogen peroxide in Ionosol T with dextrose is infused, the infusion is then stopped and 250 microcuries of RISA is injected into the catheter. Following this, 50 ml of the peroxide solution is infused. The procedure is then completed and the catheter and needle removed. Scans are done at 24, 48, 72, and occasionally 96 hours. The procedure is carried out completely on an out-patient basis.

Malignancies of the brain, extremity, thorax, abdomen and pelvis have been studied. No positive localization has occurred in lesions other than malignant tumors. In 78 scans, three false negative and one false positive scans have resulted. The false negative scans represented two cases of pulmonary metastasis and probably demonstrate an inability to infuse adequately this area as yet. One false negative scan was a poorly vascularized recurrent carcinoma of the thyroid. The false positive scan occurred in a patient with an extremity rhabdomyosarcoma. Pelvic metastases were diagnosed by the scan, but at surgery, these were not found.

#### *Peripheral Blood Changes Following Infusion of Hydrogen Peroxide Into the Carotid Artery*

Peripheral blood studies on patients receiving adjunctive  $H_2O_2$  therapy demonstrated an increase in one or more of the formed blood elements when the  $H_2O_2$  was infused in the internal or common carotid arteries. This phenomenon was not observed with  $H_2O_2$  infusion in other arteries.<sup>24</sup>

A threefold increase in circulating platelets and reticulocytes has been observed in rabbits following the infusion of hydrogen peroxide in "Ionosol-T" into the common

carotid artery in contrast to the increase in controls. The maximum increase was 24 hours after infusion. A threefold increase in one or more of the formed elements in the peripheral circulation (platelets, reticulocytes, or white blood cells) has been noted in 11 of 13 patients being infused with a solution of hydrogen peroxide into either the internal or common carotid artery. Studies are in progress to determine the nature and mechanisms of the observed stimulation and to delineate any humoral factors which might be involved. A relationship between a possible humoral factor and "erythropoietin" is being investigated.

#### *The Effect of Intra-arterial Hydrogen Peroxide on Clostridium Perfringens Infection*

The success of hyperbaric oxygen on aerobic "gas gangrene" infections prompted the use of regional intra-arterial  $H_2O_2$  in the therapy of these infections.<sup>14</sup> Clostridial myositis was produced in 48 rabbits by injection of a *Clostridium perfringens*-epinephrine preparation into the left thigh. Twenty-four of these rabbits were treated with intermittent infusions of 0.18 per cent hydrogen peroxide in normal saline with tolazoline hydrochloride (Priscoline). Twenty-four control rabbits were treated with intermittent infusions of a normal saline with tolazoline hydrochloride (Priscoline). The hydrogen peroxide-treated rabbits had a mortality of 45.9 per cent compared with a 87.6 per cent mortality in the control group. These mortality figures suggest that intra-arterial hydrogen peroxide may be of benefit in the treatment of clostridial myositis.

#### *Acceleration of Wound Healing by Intra-arterial Hydrogen Peroxide*

During the early studies in the treatment of patients with intra-arterial hydrogen peroxide and irradiation therapy, it was found that the wounds would heal at a much faster rate and with less scar formation. As a result of this, wounds that were refractory to conventional modes of therapy were treated with intra-arterial hydrogen

peroxide either alone or in combination with intra-arterial antibiotics.<sup>14</sup> The techniques used were daily or twice daily infusions of intra-arterial hydrogen peroxide, with or without intra-arterial antibiotics in 25 patients. All refractile wounds were healed promptly by this method. Several amputations were avoided. Further investigation of tensile strength, scar formation and role of healing in calibrated wounds in animals should be performed.

#### SUMMARY

Investigation of dilute solutions of hydrogen peroxide as an improved method of oxygenating tissues over hyperbaric oxygenation has been conducted. Hydrogen peroxide given intra-arterially in the regional system or directly to the exterior of an organ is decomposed into oxygen and water and produces oxygen tensions ranging from 3 to 8 atmospheres pressure regionally. This does not require lung transport, can be given continuously over long periods of time, can be administered by a single physician without expensive equipment and large teams and avoids decompression and compression hazards, as well as pulmonary and CNS toxicity of hyperbaric oxygenation. Hydrogen peroxide has been demonstrated to be an adjunctive source of oxygen for the anoxic or ischemic heart and can improve resuscitation in refractile arrhythmias or cardiac arrest. Intra-arterial infusion has been noted to reverse the atherosclerotic process, potentiate the effect of irradiation on malignant tumors, increase the localization of radioisotopes in malignant tumors, protect against *Clostridium welchii* infections, promote wound healing and serve as an excellent source of regional oxygenation without significant systemic toxicity. Further investigation in all areas is necessary to establish the quantitative value and limitations of  $H_2O_2$ .

#### REFERENCES

- 1 URSCHEL, H. C., JR., FINNEY, J. W., BALLA, G. A. AND MALLAMS, J. T.: "Regional oxygenation of the ischemic myocardium with hydrogen peroxide," *Surg. For., Amer. Coll. of Surg., Clin. Congress*, 15:273, 1964.

- 2 MALLAMS, J. T., FINNEY, J. W. AND BALLA, G. A.: "The use of hydrogen peroxide as a source of oxygen in a regional intra-arterial infusion system," *Southern Med. J.*, 55:230, 1962.
- 3 ABEATICI, S., DE NUNO, TH. AND LAUGERI, V.: "Sulle modificazioni quantitative dei gas ematici da somministrazione endovenosa di soluzioni di perossido d'idrogeno," *Chirurgia e Patologia Sperimentale*, 40, fasc. 2o, 1956.
- 4 JAY, B. E., FINNEY, J. W., BALLA, G. A. AND MALLAMS, J. T.: "The supersaturation of biologic fluids with oxygen by the decomposition of hydrogen peroxide," *Tex. Rpts. Biol. and Med.*, 22:106, 1964.
- 5 URSCHEL, H. C., JR., FINNEY, J. W., BALLA, G. A., RACE, G. J. AND MALLAMS, J. T.: "Effects of hydrogen peroxide on the cardiovascular system," *Proc. Third International Symposium on Hyperbaric Med.* (1965), in press.
- 6 URSCHEL, H. C., FINNEY, J. W., MORALES, A. R., BALLA, G. A., RACE, G. J. AND MALLAMS, J. T.: "Cardiac resuscitation with hydrogen peroxide," *Ann. Thor. Surg.*, 2:665, 1966.
- 7 FINNEY, J. W., JAY, B. E., RACE, G. J., URSCHEL, H. C., MALLAMS, J. T. AND BALLA, G. A.: "Removal of cholesterol and other lipids from experimental animal and human atherosclerotic arteries by dilute hydrogen peroxide," *Angiology*, 17:223, 1966.
- 8 FINNEY, J. W., BALLA, G. A., JAY, B. E., RACE, G. J., URSCHEL, H. C., GREENLEE, R. G. AND MALLAMS, J. R.: "Removal of cholesterol and other lipids from human atherosclerotic arteries by dilute hydrogen peroxide," *Proc. Third International Symposium on Hyperbaric Med.*, in press.
- 9 MALLAMS, J. T., BALLA, G. A. AND FINNEY, J. W.: "Regional oxygenation and radiation. Current status," *Am. J. Roent., Rad. Ther. and Nuclear Med.*, 93:160, 1965.
- 10 MALLAMS, J. T., FINNEY, J. W. AND BALLA, G. A.: "Regional oxygenation and its effect upon radiation therapy and isotope localization," *Proc. Third International Symposium on Hyperbaric Med.*, in press.
- 11 FINNEY, J. W., COLLIER, R. E., BALLA, G. A., TOMME, J. W., WAKLEY, J., RACE, G. J., URSCHEL, H. C., D'ERRICO, A. D. AND MALLAMS, J. T.: "The preferential localization of radioisotopes in malignant tissue by regional oxygenation," *Nature*, 202:1172, 1964.
- 12 FINNEY, J. W., COLLIER, R. E., BALLA, G. A., TOMME, J. W., WAKLEY, J., RACE, G. J., URSCHEL, H. C., D'ERRICO, A. D. AND MALLAMS, J. T.: "The preferential localization of radioisotopes in malignant tissue by regional oxygenation," *Year Book of Radiology*, (Therapeutics Sect.), 1965-66.
- 13 BRADLEY, B. E., VEDROS, N. A., DEFALCO, A. J., LAWSON, D. W., VINEYARD, G. C. AND URSCHEL, H. C.: "The effect of intra-arterial hydrogen peroxide in rabbits infected with *Clostridium perfringens*," *J. Trauma*, 5:799, 1965.
- 14 BALLA, G. A., FINNEY, J. W., ARONOFF, B. L., BYRD, D. L., RACE, G. J., MALLAMS, J. T. AND DAVIS, G.: "Use of intra-arterial hydrogen peroxide to promote wound healing. Part I—Regional intra-arterial therapy—technical surgical aspects. Part II—Wound healing—clinical aspects," *Amer. J. Surg.*, 108:621, 1964.
- 15 FINNEY, J., URSCHEL, H. C., BALLA, G. A. AND RACE, G. J.: "Protection of the ischemic myocardium with DMSO alone or in combination with hydrogen peroxide," *Ann. New York Acad. Sci.*, in press.
- 16 URSCHEL, H. C., JR., FINNEY, J. W., BALLA, G. A., MALLAMS, J. T. AND RACE, G. J.: "Myocardial protection during aortic cross-clamping with hydrogen peroxide," presented at the American Heart Association, 1964, *Circulation*, 30:172, 1964 (Abstract).
- 17 SCHOOLS, G. S., SMITH, K., RACE, G. J., URSCHEL, H. C., JR., FINNEY, J. W., BALLA, G. A. AND MALLAMS, J. T.: "Effects of nebulized hydrogen peroxide on blood gases and on normal and bronchitic animals," presented at the National Tuberculosis meeting, 1965, *Amer. Rev. Resp. Dis.*, (Abstract), in press.
- 18 URSCHEL, H. C., JR., FINNEY, J. W., DYLL, J. W., BOLAND, G. L., RACE, G. J., JAY, B. E., DAVIS, G. AND BALLA, G. A.: "Treatment of arteriosclerotic obstructive cerebrovascular disease with hydrogen peroxide," *Angiology*, (in press).
- 19 MALLAMS, J. T., BALLA, G. A. AND FINNEY, J. W.: "Regional oxygenation and irradiation in the treatment of malignant tumors," *Prog. Clin. Cancer*, 1:137, 1965.
- 20 ARONOFF, B. L., BALLA, G. A., FINNEY, J. W., COLLIER, R. E. AND MALLAMS, J. T.: "Regional oxygenation in the diagnosis and management of intra-abdominal and retroperitoneal neoplasms," *Cancer*, 18:1244, 1965.
- 21 MALLAMS, J. T., BALLA, G. A. AND FINNEY, J. W.: "Regional oxygenation and radiation therapy: Current status," *Year Book of Radiology*, (Therapeutics Section), 1966.
- 22 FINNEY, J. W., BALLA, G. A., COLLIER, R. E., WAKLEY, J., URSCHEL, H. C. AND MALLAMS, J. T.: "Differential localization of isotopes in tumors through the use of intra-arterial hydrogen peroxide. Part I—Basic Science," *Amer. J. Roent. Rad. Ther. and Nuclear Med.*, 94:783, 1965.
- 23 COLLIER, R. E., BALLA, G. A., FINNEY, J. W., D'ERRICO, A., TOMME, J. W., MILLER, J. E. AND MALLAMS, J. T.: "Differential localization of isotopes in tumors through the use of intra-arterial hydrogen peroxide. Part II—Clinical Evaluation," *Amer. J. Roent. Rad. Ther. and Nuclear Med.*, 94:789, 1965.
- 24 FINNEY, J. W., BALLA, G. A., MALLAMS, J. T. AND RACE, G. J.: "Peripheral blood changes in humans and experimental animals following the infusion of hydrogen peroxide into the internal carotid artery," *Angiology*, 16:62, 1965.

For reprints, please write: Dr. Urschel, 3810 Swiss Avenue, Dallas.

Readers are invited to submit articles for *Progress in Cardiovascular Surgery*. Please submit material to David P. Boyd, M.D., 605 Commonwealth Avenue, Boston, Massachusetts.

## Cardiovascular Effects of Hydrogen Peroxide: Current Status

Harold C. Urschel, Jr.  
*Dis Chest* 1967;51; 180-192  
DOI 10.1378/chest.51.2.180

**This information is current as of October 25, 2009**

<b>Updated Information &amp; Services</b>	Updated Information and services, including high-resolution figures, can be found at: <a href="http://chestjournal.chestpubs.org/content/51/2/180">http://chestjournal.chestpubs.org/content/51/2/180</a>
<b>Open Access</b>	Freely available online through CHEST open access option
<b>Permissions &amp; Licensing</b>	Information about reproducing this article in parts (figures, tables) or in its entirety can be found online at: <a href="http://www.chestjournal.org/site/misc/reprints.xhtml">http://www.chestjournal.org/site/misc/reprints.xhtml</a>
<b>Reprints</b>	Information about ordering reprints can be found online: <a href="http://www.chestjournal.org/site/misc/reprints.xhtml">http://www.chestjournal.org/site/misc/reprints.xhtml</a>
<b>Email alerting service</b>	Receive free email alerts when new articles cite this article. Sign up in the box at the top right corner of the online article.
<b>Images in PowerPoint format</b>	Figures that appear in CHEST articles can be downloaded for teaching purposes in PowerPoint slide format. See any online article figure for directions

A M E R I C A N C O L L E G E O F



P H Y S I C I A N S<sup>®</sup>